

**A Guide
to
Transthyretin Amyloidosis
ATTR**



What is amyloidosis?

Amyloidosis is a systemic disorder characterized by extra cellular deposition of a protein-derived material, known as amyloid, in multiple organs. Amyloidosis occurs when native or mutant polypeptides misfold and aggregate as fibrils. The amyloid deposits cause local damage to the cells around which they are deposited leading to a variety of clinical symptoms. There are at least 23 different proteins associated with the amyloidosis.

The most well-known type of amyloidosis is associated with a hematological disorder, in which amyloid fibrils are derived from monoclonal immunoglobulin light-chains (AL amyloidosis). This is associated with a plasma cell disorder, closely related to and can co-exist with multiple myeloma.

Chronic inflammatory conditions such as rheumatoid arthritis or chronic infections such as bronchiectasis are associated with chronically elevated levels of the inflammatory protein, serum amyloid A, which may misfold and cause AA amyloidosis.

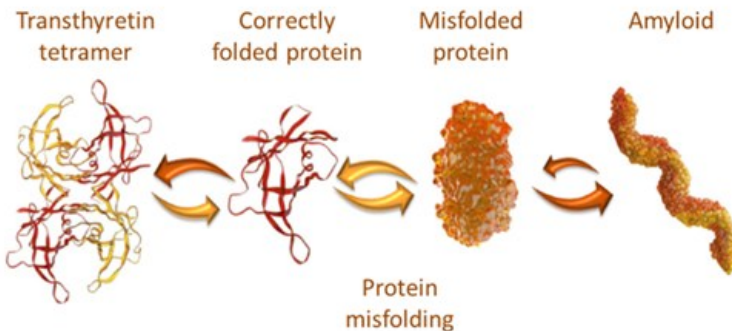
The hereditary forms of amyloidosis are autosomal dominant diseases characterized by deposition of variant proteins, in distinctive tissues. The most common hereditary form is transthyretin amyloidosis (ATTR) caused by the misfolding of protein monomers derived from the tetrameric protein transthyretin (TTR). Mutations in the gene for TTR frequently result in instability of TTR and subsequent fibril formation. Closely related is wild-type TTR in which the native TTR protein, particularly in the elderly, can destabilize and re-aggregate causing non-familial cases of TTR amyloidosis.

Other proteins that have been associated with forms of hereditary amyloidosis include apolipoproteins AI and AII, cystatin C, lysozyme, fibrinogen A α -chain and gelsolin.

This pamphlet will concentrate on the most common form of hereditary amyloidosis – ATTR, including a discussion of the non-hereditary wild-type TTR disease.

What is transthyretin amyloidosis (ATTR)?

ATTR is caused by deposition of TTR amyloid fibrils in various tissues. The hereditary form of ATTR is caused by autosomal dominant mutations in the TTR gene. The prevailing theory for amyloid formation associated with the amyloidogenic mutations is based on the observations that changes of amino acids are associated with destabilization and dissociation of the TTR tetramer, leading to abnormally folded monomers that ultimately self-assemble to amyloid fibrils (Fig. 1). These TTR amyloid fibrils are then deposited extracellularly in various tissues. There are more than 120 reported TTR single point mutations that have been associated with hereditary ATTR.



How frequent is hereditary TTR amyloidosis (ATTR)?

Familial ATTR is a rare disorder, with unequal distribution around the world. Certain clusters (predominately causing familial amyloid polyneuropathy) have been described, mainly in Portugal, Japan, and Northern Sweden. This form of the disease (related to the Val30Met mutation) was first described in the Porto area of Portugal and is sometimes referred to as the Portuguese type of amyloidosis. Estimates have been made for the incidence and prevalence of this type of ATTR. In Europe, the incidence is estimated as 0.003 cases per 10,000 per year (or 0.3 new cases per year per 1 million inhabitants), with a prevalence estimate of

0.052 per 10,000 (or 5.2 cases per 1 million inhabitants). In the endemic area of Northern Sweden with a population of 600,000 individuals, the frequency of the gene is 1.5%, however, the penetrance is relatively low, and most patients develop the disease after the age of 50 years. The size of the patient population in the US is estimated to not exceed 6,400 patients. In Japan, approximately 400 patients with hereditary ATTR have been reported.

The prevalence of ATTR dominated by cardiomyopathy is less well known, but is almost certainly underdiagnosed. The two most well documented mutations leading to cardiomyopathy are Val122Ile and Thr60Ala. Val122Ile is seen in populations of West-African descent, with a carrier frequency as high as 3.5-4%. This West-African lineage is particularly common in the African American population. Recent data suggest that the penetrance of the Val122Ile mutation is less than 50% by the age of 80. This would mean that among the Val122Ile carrier population who are older than age 60 (approximately 150,000 individuals), potential case-load in the US may be up to 75,000. The Thr60Ala mutation, known as Ala60, is found in populations of Irish descent. The carrier frequency is unknown. The penetrance of Thr60Ala is less well known but thought to be very high. This mutation results in a more pronounced manifestation of neuropathic phenotype than Val122Ile in addition to a cardiomyopathy.

Clinical aspects of ATTR

ATTR is a systemic disorder resulting in polyneuropathy, autonomic neuropathy, cardiomyopathy and often a mixture of these manifestations.

Polyneuropathy

The main neuropathic feature of ATTR is a progressive sensorimotor and autonomic neuropathy. Val30Met is the most common TTR mutation in patients presenting with neuropathy. The disease onset is usually in the third or fourth decade, but can occur later. The disease initially affects small unmyelinated nerve

fibers which mediate pain and temperature sensations, and autonomic nerve functions. Typically, sensory neuropathy with numbness, tingling and lack of feeling starts in the feet and progresses proximally. By the time the sensory neuropathy has progressed to the knee level, the hands have usually become involved. With progression of the neuropathy, larger nerve fibers become involved, impacting position and vibratory sensations, and reflexes. Carpal tunnel syndrome with median nerve compression is common and may be the first presenting symptom.

Motor neuropathy usually follows within a few years. Footdrop, wristdrop and disability of the hands and feet are frequent symptoms of motor neuropathy leading to difficulties in walking and performing fine hand movements.

Subjects with the Val30Met mutation also have evidence of cardiac involvement with conduction disease manifestation early in the course of the disease. As the disease progresses, features of a restrictive cardiomyopathy develop with resulting heart failure and atrial arrhythmias.

Autonomic Neuropathy

Autonomic neuropathy often accompanies the sensory and motor deficits and may represent the initial disease presentation. Symptoms include orthostatic hypotension, constipation alternating with diarrhea, nausea, vomiting, delayed gastric emptying, erectile dysfunction, anhydrosis, urinary retention and incontinence. The gastrointestinal involvement results in weight loss and ultimately in wasting and malnutrition.

Cardiomyopathy

Cardiomyopathy may be the predominant feature of ATTR for some patients or may develop after the onset of neuropathy in patients with familial amyloid polyneuropathy. ATTR cardiomyopathy occurs when TTR amyloid fibrils infiltrate the myocardium, (middle muscle of the heart wall) causing myocardial stiffness, reduction in chamber capacitance and restrictive filling patterns seen on Doppler echocardiography. This initially results in dias-

tolic dysfunction, and without treatment will progress to symptomatic heart failure typical of restrictive cardiomyopathy.

The phenotype is characterized by progressive heart failure, often with severe right-sided symptoms. When a low cardiac output supervenes, renal impairment may occur, although autopsy studies have not shown renal involvement by amyloid deposits.

The onset of ATTR cardiomyopathy may occur at any age from the third decade onward, with the typical age of onset > 55 in patients with the Val122Ile mutation. Cardiac involvement can present with conduction system disease (sinus node or atrioventricular node dysfunction) or congestive heart failure including shortness of breath, peripheral edema, syncope (loss of consciousness), labored breath on exertion, generalized fatigue. The echocardiographic findings often show thicker ventricular walls than in AL amyloidosis and include thickened ventricular walls with a normal to small left ventricular cavity, increased myocardial echogenicity, normal or mildly reduced ejection fraction, often with evidence of diastolic dysfunction and severe impairment of contraction along the longitudinal axis, and bi-atrial dilation with impaired atrial contraction. Subjects with TTR amyloid usually have more severe left ventricular thickening than those with AL amyloid.

Similar to AL amyloidosis, the voltage on the ECG may be normal, although low voltage may be seen despite the increased wall thickness on echocardiography. Low voltage is a marker of advanced disease. As many as 15% of subjects with TTR amyloid can have electrocardiographic evidence of left ventricular hypertrophy.

Ocular manifestations

The TTR gene is also expressed in the retinal pigment epithelium of the eye, and approximately 20% of amyloidogenic TTR mutations are associated with vitreous opacities derived from amyloid, and may lead to visual impairment. TTR amyloid can be vis-

ualized in the vitreous body with typical cotton wool inclusions. Demonstration of such deposits is helpful for the diagnosis of ATTR.

Other organs

Unlike AL amyloidosis, renal involvement is rare in ATTR except for patients with TTR V30M, which it may be a presenting feature. When renal involvement is present, proteinuria is the usual manifestation. Very rarely the renal involvement leads to end-stage renal disease requiring dialysis or renal transplantation.

Non-hereditary ATTR

Wild-type ATTR cardiomyopathy occurs when wild-type TTR forms fibrils, which then deposit as amyloid, primarily in cardiac tissue, primarily in men. This deposition proceeds gradually and becomes clinically manifested (and is thereby usually diagnosed) in the 6th or 7th decade. Other than carpal tunnel syndrome and possibly the lumbar or cervical spine and tendons, deposition is clinically limited to the heart. The clinical presentation is similar to that described for the hereditary form of ATTR cardiomyopathy. The clinical prevalence of wild-type ATTR cardiomyopathy is unknown, but autopsy studies suggest that up to 22-25% of individuals >80 years old have demonstrable TTR amyloid deposits in cardiac tissue, although in most cases the degree of deposition is mild. 10-15% of patients who have heart failure and a preserved EF have TTR cardiac amyloid demonstrated by non-invasive scanning with DPD or PYP scanning.

When should ATTR be suspected?

The multisystemic involvement in hereditary or familial ATTR makes the disease a possible differential diagnosis in many instances. It would be particularly important to consider the diagnosis when one, or especially several of the following symptoms are present:

- when there is a known family history of neuropathic disease, especially if associated with heart failure

- In cases of neuropathic pain or sensory disturbances of unknown cause
- when there is a history of carpal tunnel syndrome (without obvious cause), particularly if bilateral and requiring surgery
- In patients with a cardiomyopathy and concomitant biceps tendon rupture (Popeye's sign)
- in patients with gastro-intestinal motility disturbances or autonomic nerve dysfunction of unknown cause
- if there is cardiac disease characterized by thickened ventricular walls, diastolic dysfunction, or overt cardiomyopathy, particularly in the presence of normal or preserved ejection fraction and in the absence of hypertension
- when a patient presents with complete heart block of unknown origin and echocardiographic abnormalities
- when there are vitreous body inclusions of cotton wool type

As there are many pitfalls in the diagnosis of ATTR, it is generally recommended that patients with possible ATTR are referred to a specialist center with experience in the diagnosis and management of amyloidosis.

Diagnosis of TTR amyloidosis

TTR amyloidosis is a systemic disease in which amyloid deposits can be visualized in most tissues such as skin, fat pad, rectal mucosa, gastric mucosa, nerve tissue or, myocardium. Tissue biopsy should be performed, ideally of an affected organ. Staining with Congo red, which gives a characteristic apple green color when viewed under polarizing microscopy, can confirm amyloidosis. Confirmation of the precursor protein being TTR can be made with either immunohistochemistry (though this method is highly dependent on pathologist experience) or by mass spectroscopy (considered the gold standard). As the distribution of amyloid may be patchy in certain tissues, a negative biopsy does not rule

out the diagnosis of amyloidosis, although it is almost universally positive in cardiac amyloidosis if the echocardiogram shows typical findings.

Once amyloid is demonstrated, then the type of precursor protein should be identified. If a tissue biopsy is negative for amyloid staining but the clinical suspicion for hereditary ATTR is high, the investigator may proceed directly with genotyping. However, it should be kept in mind that the penetrance of the underlying trait varies and therefore, demonstration of amyloid deposits is generally required.

Diagnosis of the hereditary form of ATTR requires demonstration of a TTR gene mutation. A history of familial disease is helpful but many patients seen with ATTR do not have a documented family history.

For the diagnosis of non-hereditary ATTR in a patient with suspicious echocardiogram, a cardiac biopsy demonstrating amyloid deposits which are positive for TTR, combined with lack of identifiable mutation in the TTR gene is generally required. Even though non-hereditary ATTR is a systemic disease, it may be difficult to demonstrate amyloid deposits in tissues other than the heart.

More recently, nuclear imaging using bone isotopes (DPD, PYP, and HMDP) has been demonstrated to have high sensitivity and specificity for identifying TTR amyloid non-invasively. These imaging techniques are easy to perform (usually in < 1.5 hours), involve minimal radiation exposure and are highly sensitive and specific (~90%) for TTR cardiac amyloidosis and can replace the need for biopsy to confirm the diagnosis. These imaging techniques must be coupled with blood and urine tests to evaluate for AL amyloidosis.

Treatment of ATTR

Until recently, there have been no US approved pharmacologic therapy available for ATTR; thus therapy was previously focused

on managing symptoms, e.g. analgesics for painful neuropathy, pacemaker implantation for heart conduction problems, diuretics for congestive heart failure, etc. Treatment with certain calcium channel blockers and possibly digitalis, should be avoided since it may accumulate in the amyloid deposits and increase the risk of heart complications.

As TTR is primarily formed in the liver, orthotopic liver transplantation was a treatment available for hereditary ATTR. This procedure can remove approximately 95% of the production of variant TTR and slow or halt the progression of the disease. Improvement of nerve function, and in particular of autonomic disturbances, has been reported, but has not been documented in systematic follow-up studies in liver transplant recipients. Cardiac disease may progress after liver transplantation, due to deposition of wild-type TTR-derived amyloid. Because of this possibility, combined liver and heart transplantation has been performed in patients with TTR amyloid cardiomyopathy. Eye opacities may develop or progress after liver transplantation as they are due to local ocular amyloid formation. It is generally considered that the best outcome of orthotopic liver transplantation is achieved when it is performed before the disease has become too advanced. Overall patient survival rate at 5 years is reported to be above 77%.

The FDA approved two agents, Onpattro and Tegsedi for the treatment of hereditary transthyretin amyloid polyneuropathy. Both agents are “silencers” or “knockdown” therapies in that they reduce the production of type variants and wild type TTR by the liver. Onpattro is a small interfering RNA (siRNA) that is administered by IV infusion every 3 weeks along with steroids and antihistamines to reduce the chance of infusion reactions. Another RNA therapy recently approved by the FDA is AMVUTTRA (vutrisiran) for ATTRv polyneuropathy. Tegsedi is an antisense oligonucleotide (ASO) that is administered by subcutaneous injection on a weekly basis. Both agents have been shown to be effective at reducing neurologic progression in patients with he-

hereditary transthyretin amyloid polyneuropathy. Wainua (eplontersen) was FDA approved in 2023 for polyneuropathy involvement. It is a once monthly subcutaneous injection which silences the production of amyloid in the liver.

An alternative strategy to treat transthyretin amyloidosis is by stabilizing the transthyretin protein preventing the dissociation of TTR into monomers or oligomers, which is the rate limiting step in transthyretin amyloid formation. Diflunisal is a non-steroidal anti inflammatory drug that has been repurposed to treat hereditary transthyretin amyloid polyneuropathy and has been shown to prevent progression of disease with a good safety profile. Vyndamax (tafamadis) has been approved by the FDA and is a specific and potent TTR stabilizing compound with no NSAID activity. The FDA has approved Vyndaqel and Vyndamax (tafamadis) for ATTR cardiomyopathy. In 2024 Attruby (acoramidis) has been approved for ATTR cardiac involvement.

Prognosis of ATTR

All forms of ATTR are progressive, but the rate of progression is variable and may be dependent on the clinical phenotype and the mutation. Generally, patients with the ATTR V30M mutation have a mean life expectancy of 9-11 years from symptom onset. Death is due primarily to malnutrition and cachexia, renal failure, cardiac disease or sudden death. For other more rare mutations, survival is less well documented.

The progression of ATTR when cardiomyopathy is the predominant clinical manifestation is less well documented but the prognosis is often poor with mean life expectancy from symptom onset of 5-6 years, and death due primarily from heart failure or sudden death.

Recently, two staging systems for patients with transthyretin amyloid cardiomyopathy have been developed which can provide prognostic information based on widely available biomarkers including renal function, natriuretic peptides and troponin.



**amyloidosis
foundation**

7151 N. Main Street, #2

Clarkston, MI 48346

248-922-9610

info@amyloidosis.org

www.amyloidosis.org

2024 Edition